

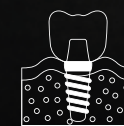
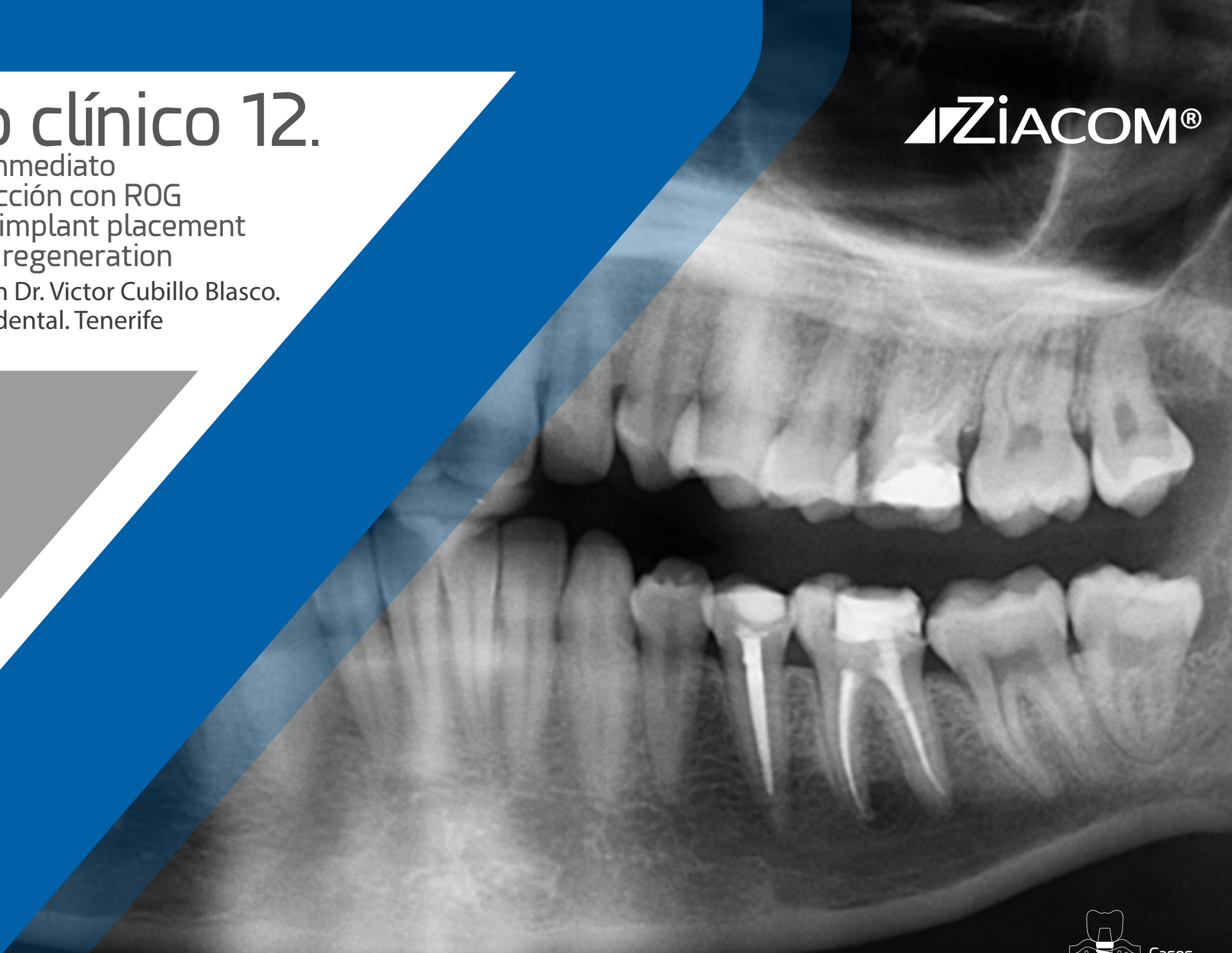Caso clínico 12.

Implante inmediato
post extracción con ROG

Immediate implant placement
with Bone regeneration

Colaboración Dr. Victor Cubillo Blasco.
Clínica Artedental. Tenerife

ZIACOM®



Casos
Clínicos

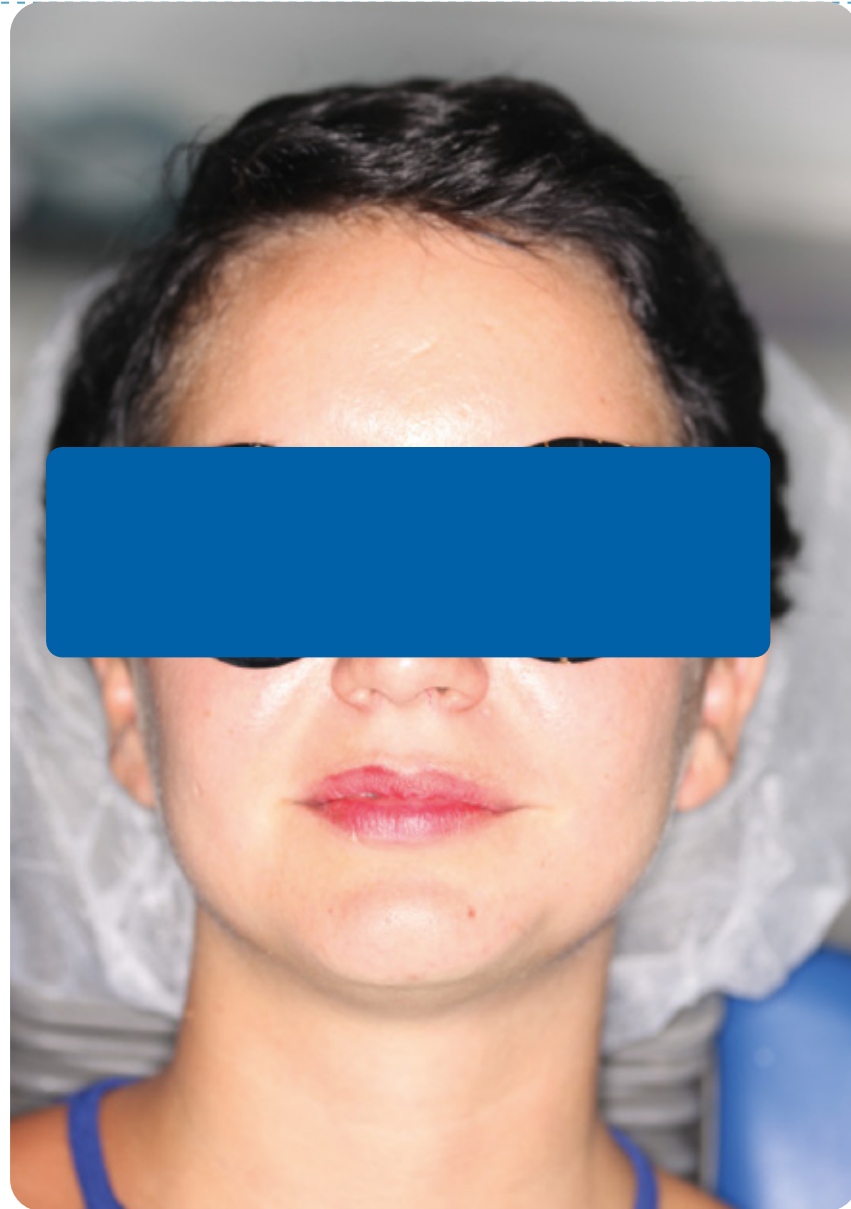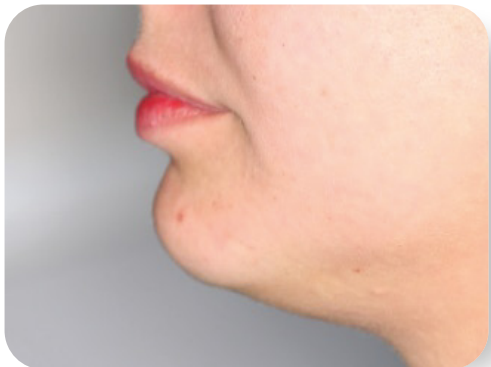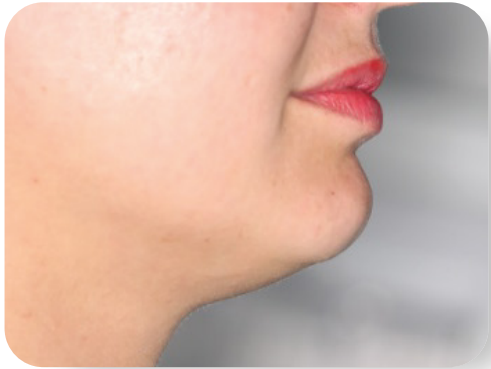- Género: Femenino
- Edad: 27
- Tratamiento: Implante inmediato con ROG
- Tipo implante: ZINIC®

- Gender: Female
- Age: 27 years old
- Treatment: Immediate implant placement with Bone regeneration.
- Type and Implan size: ZINIC®

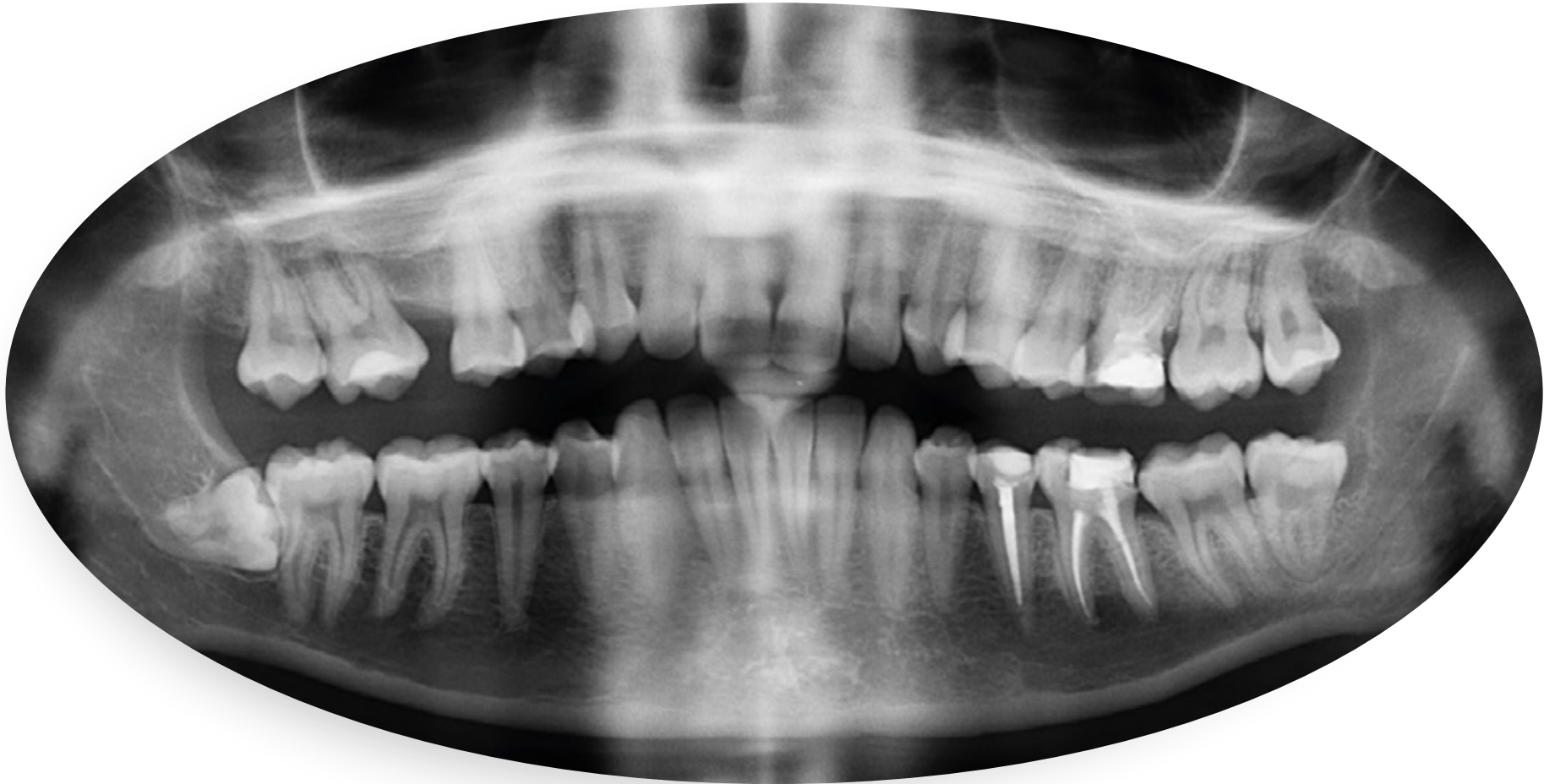


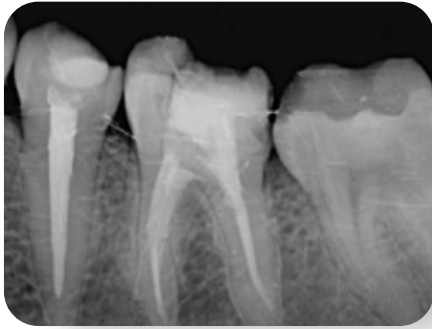
Osseonova®

ANÁLISIS FACIAL / FACIAL ANALYSIS

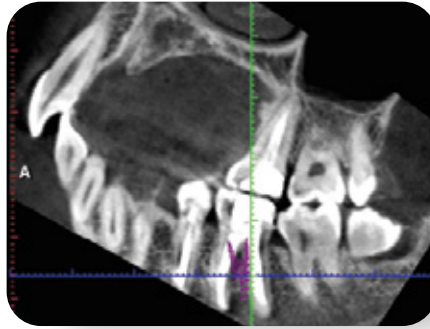


ORTOPANTOMOGRAFÍA / PANORAMIC RX

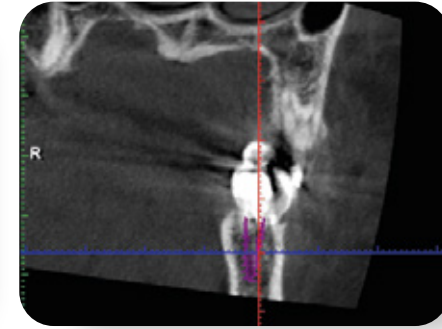




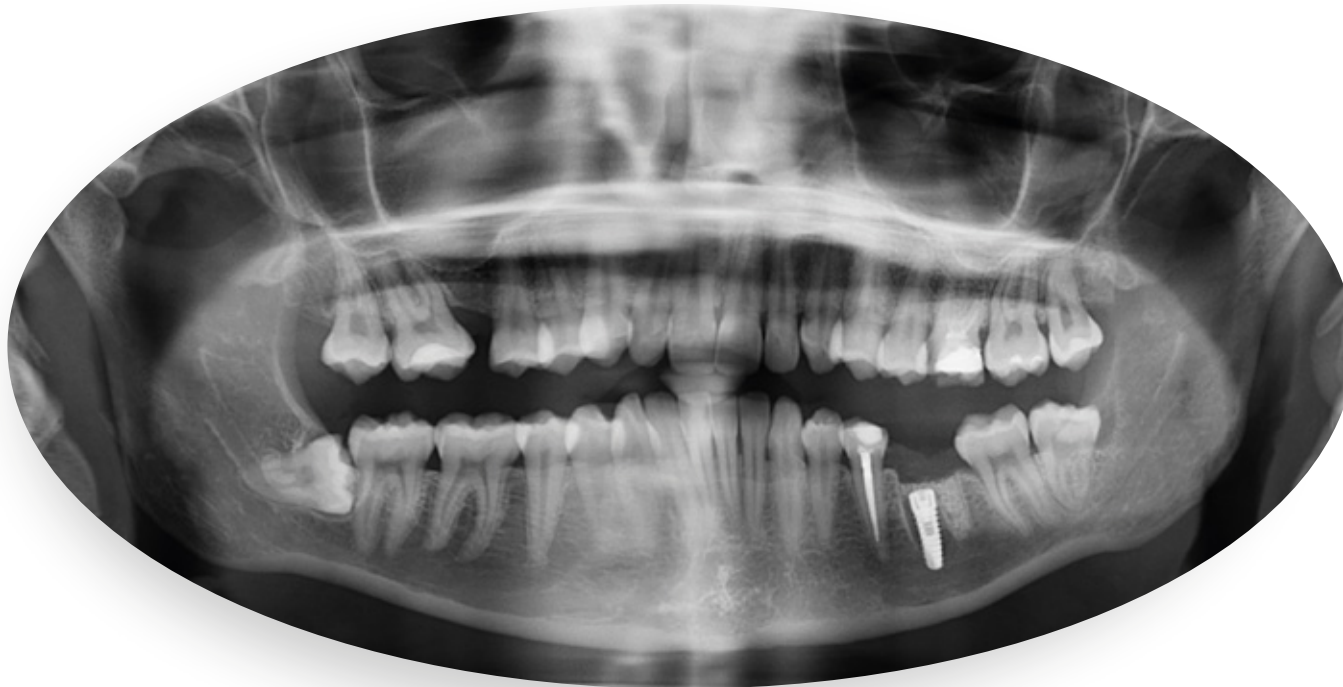
Radiografía periapical inicial/
Initial periapical x-ray

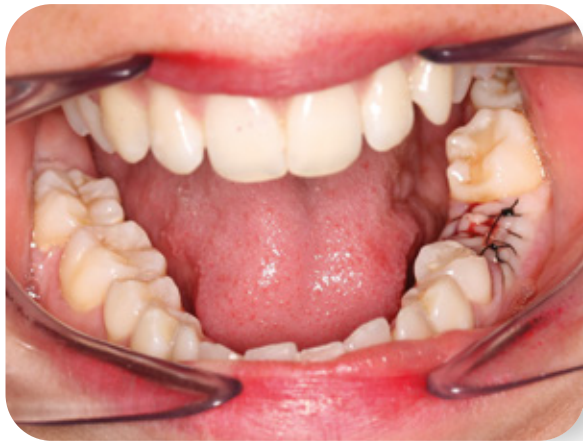

Planificación con CBCT/CBCT Plan

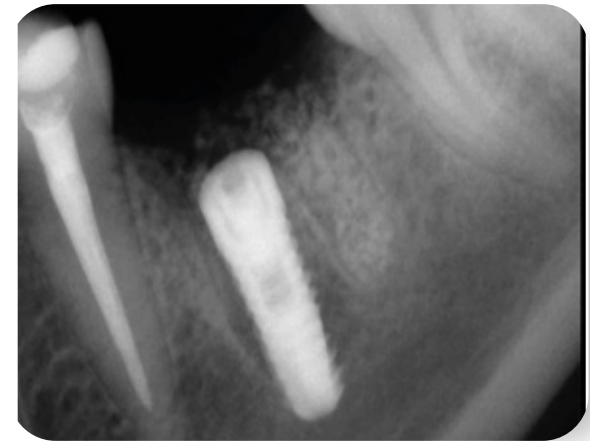
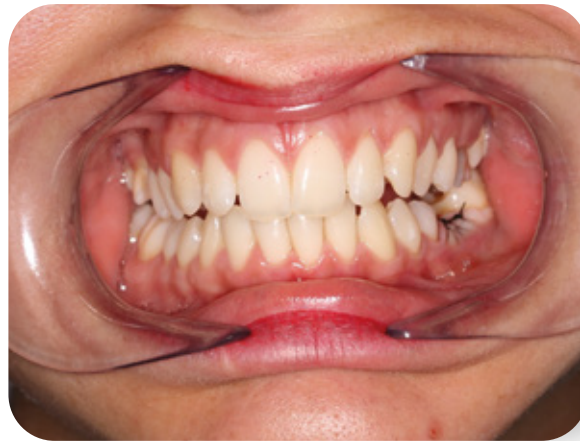

Ortopantomografía/Orthopantomography





Control a los 3 días / Postsurgical control. 3 days after



Radiografía control 3 semanas/
Control x-Ray 3 weeks